



Bloqueos de los Nervios de la Mano



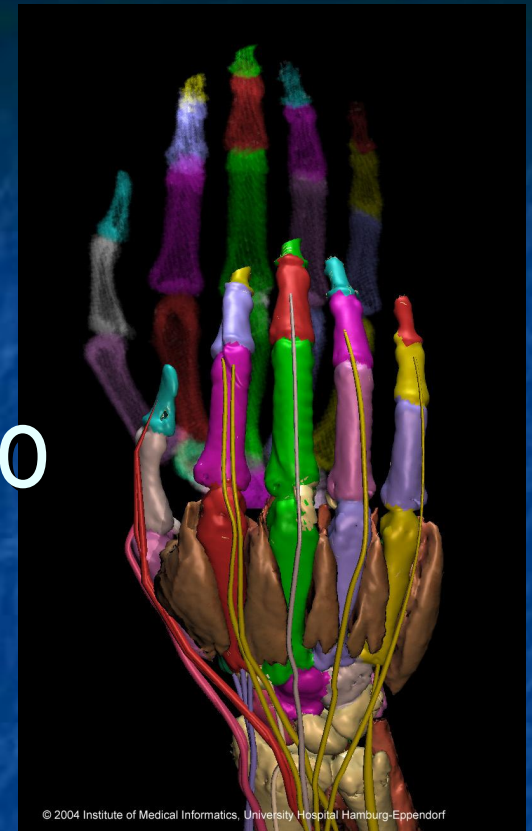
Kevin Reilly, MD

Dept of Emergency Medicine
University of Arizona
Tucson, AZ, USA

Traductor

Kenneth V. Iserson, M.D., MBA

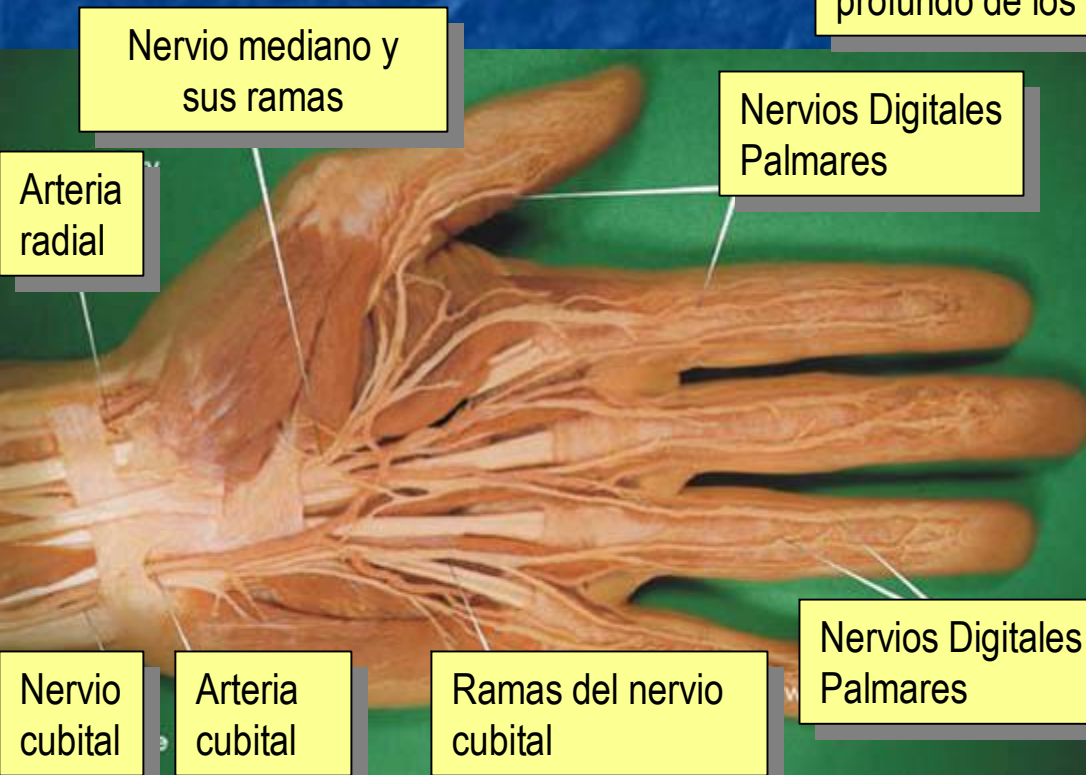
Dept of Emergency Medicine
University of Arizona
Tucson, AZ, USA



Bloqueos de los Nervios

	Inicio (minutos)	Anestesia (horas)	Analgesia (horas)
1.5% Mepivacaína (+HCO ₃)	15-20	2-3	3-5
2% Lidocaína (+HCO ₃)	15-30	2-5	3-8
0.5% Ropivacaína	15-30	4-8	5-12
0.75% Ropivacaína	10-15	5-10	6-24
0.5% Bupivacaína (or I-bupivacaína)	15-30	5-15	6-30

Bloqueos Digitales



Nervio Digital

Tendón flexor profundo de los dedos

Piel

Tendón flexor superficial de los dedos

Falange

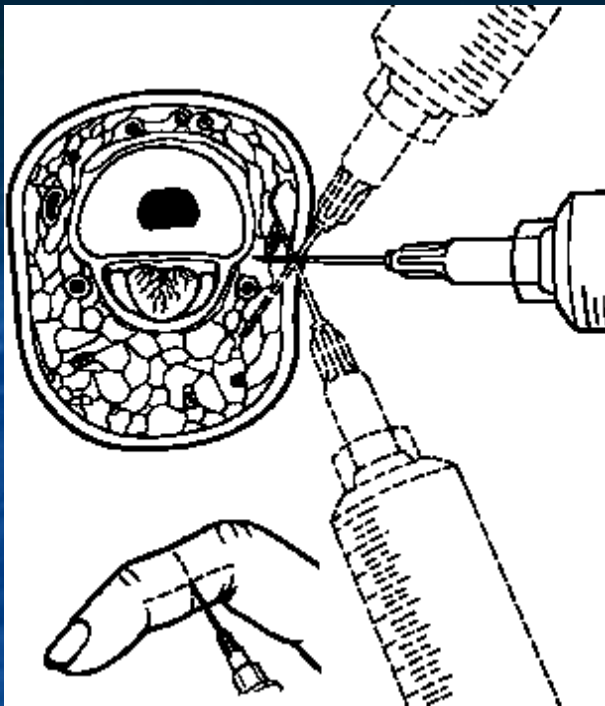
Aponeurosis palmar

Vena dorsal

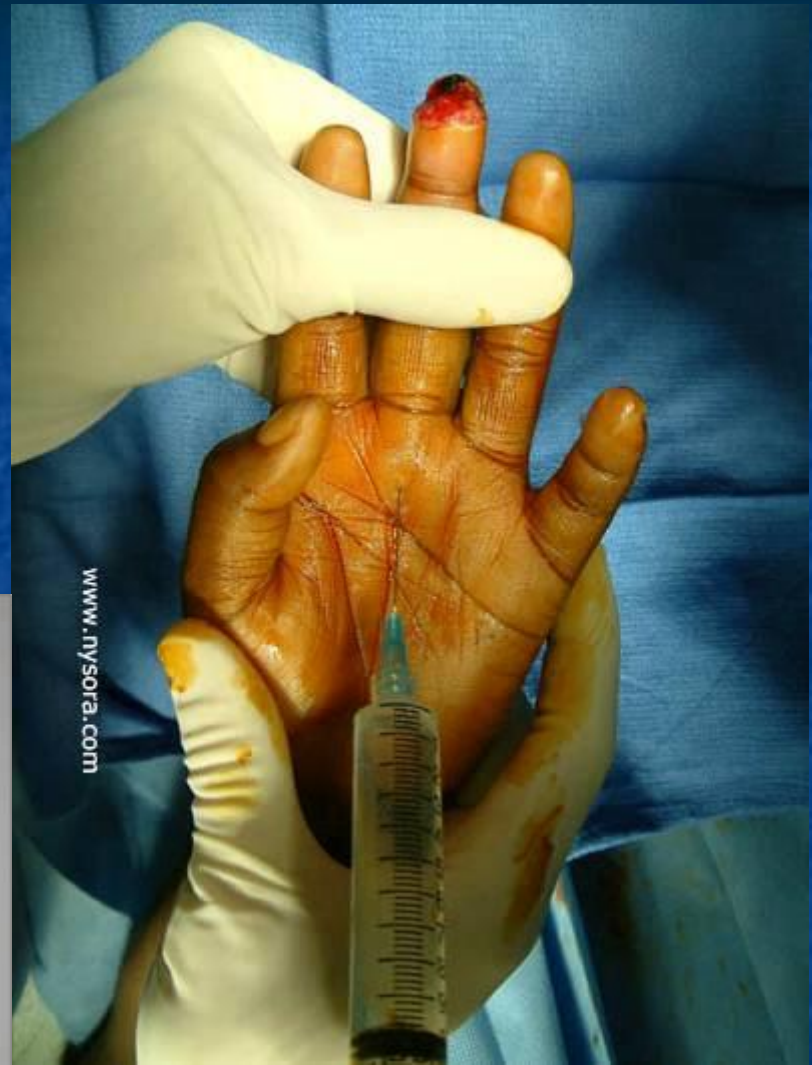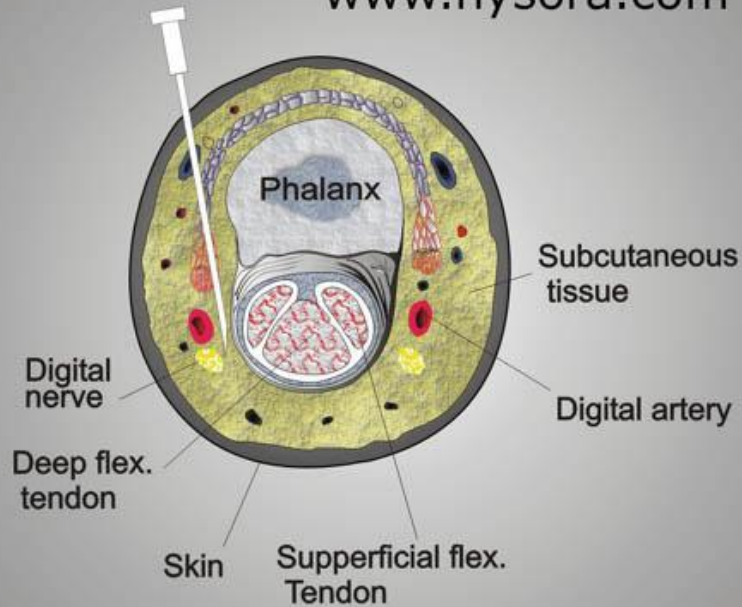
Tejido subcutáneo

Arteria Digital

Nervio Digital



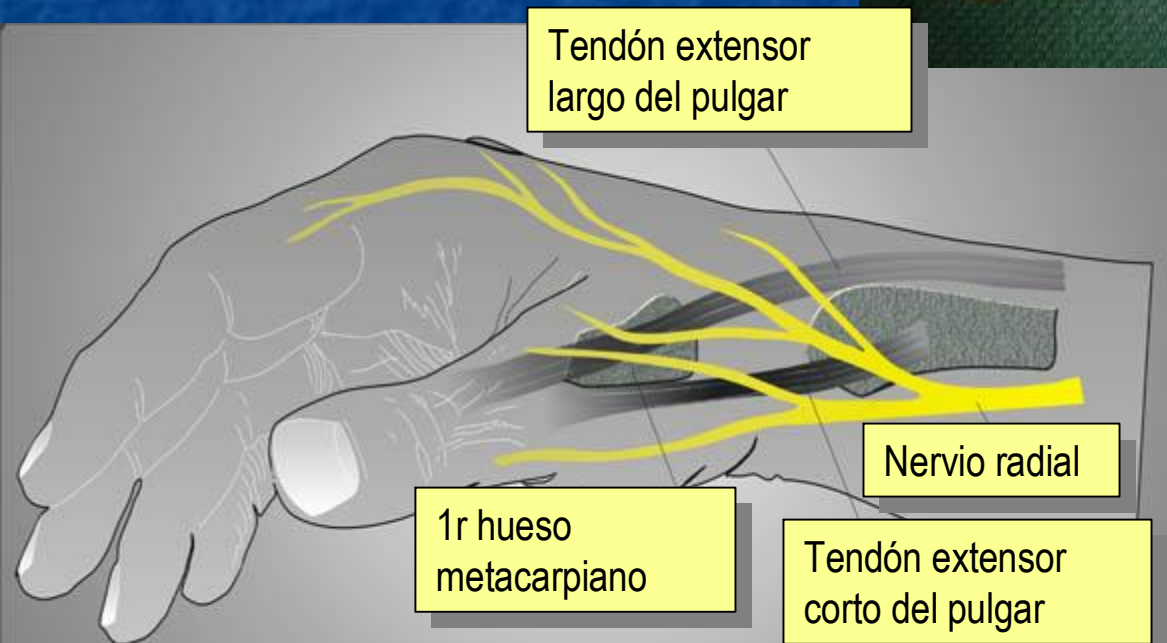
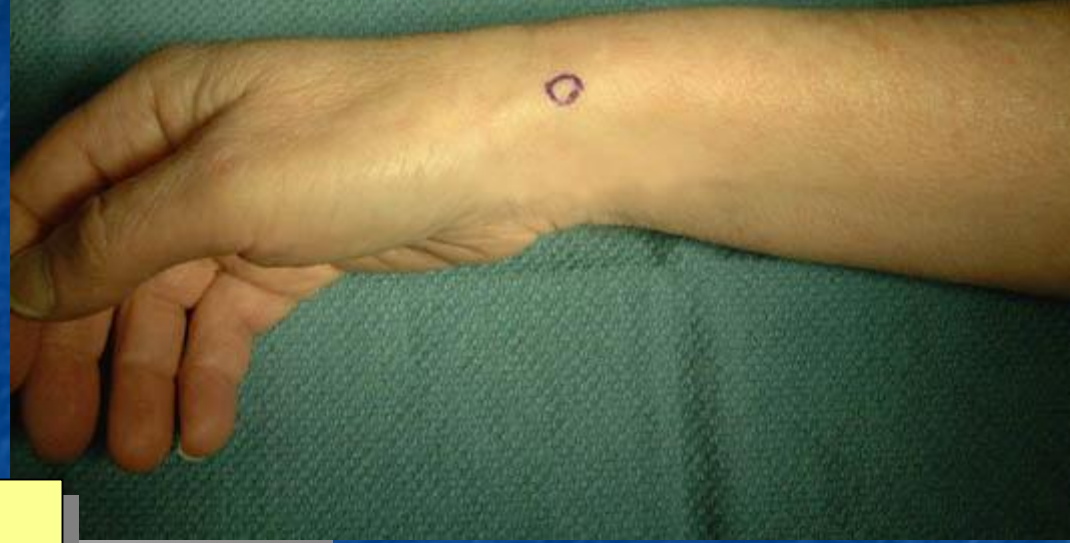www.nysora.com



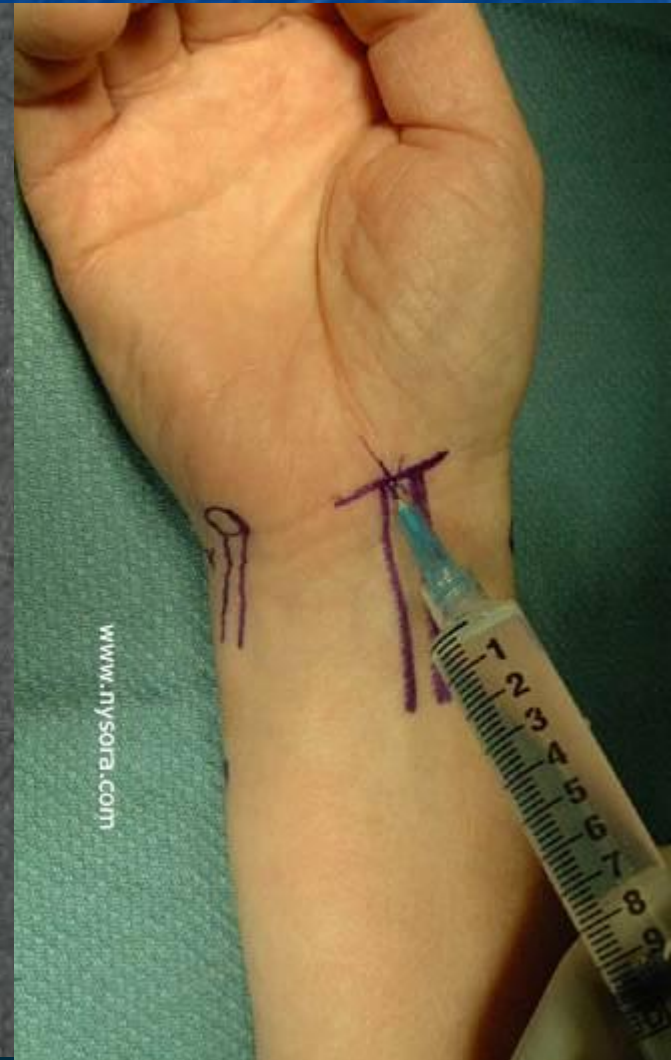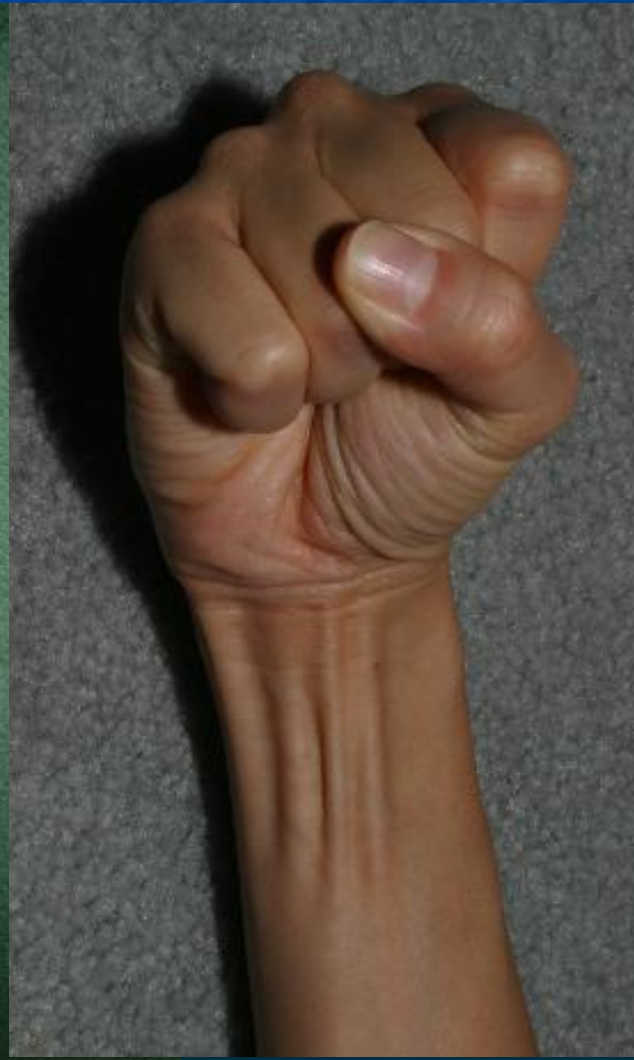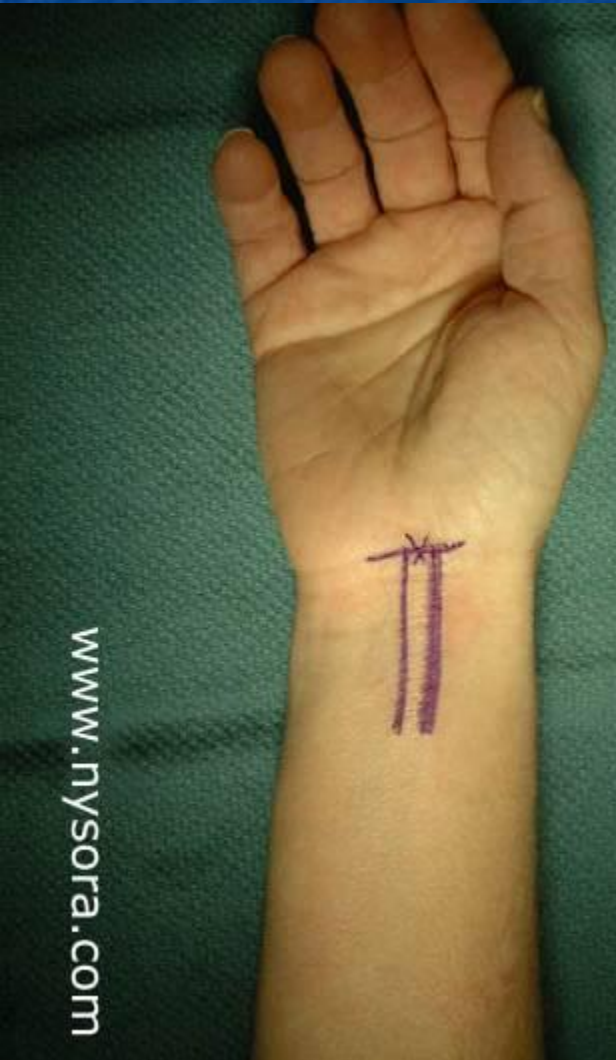www.nysora.com

www.reeme.arizona.edu

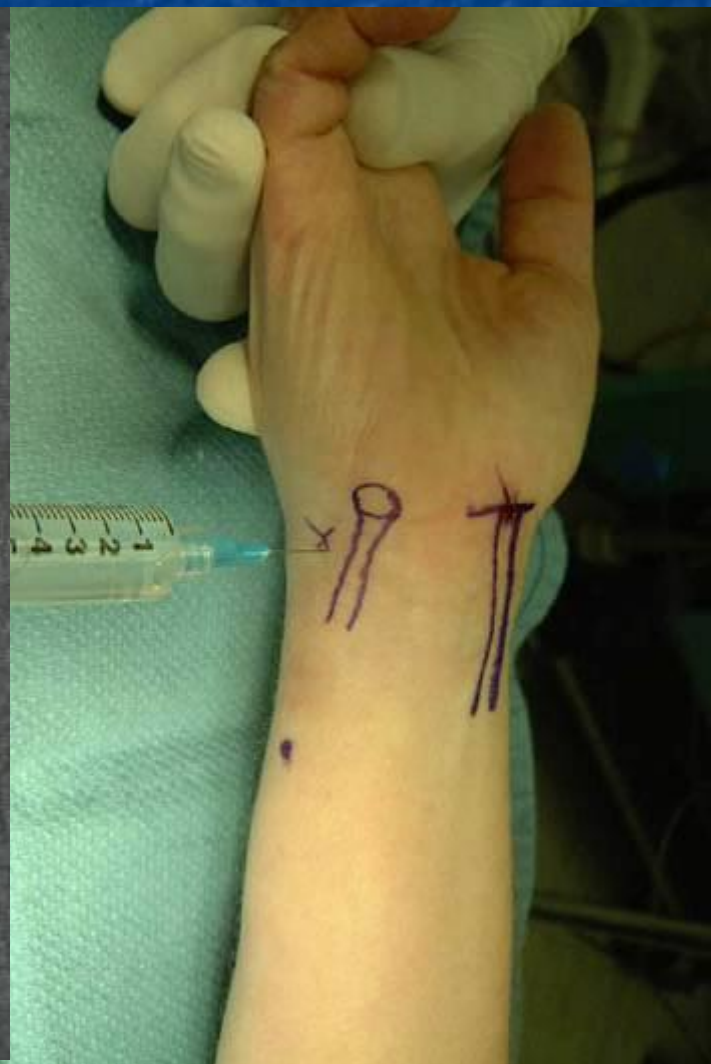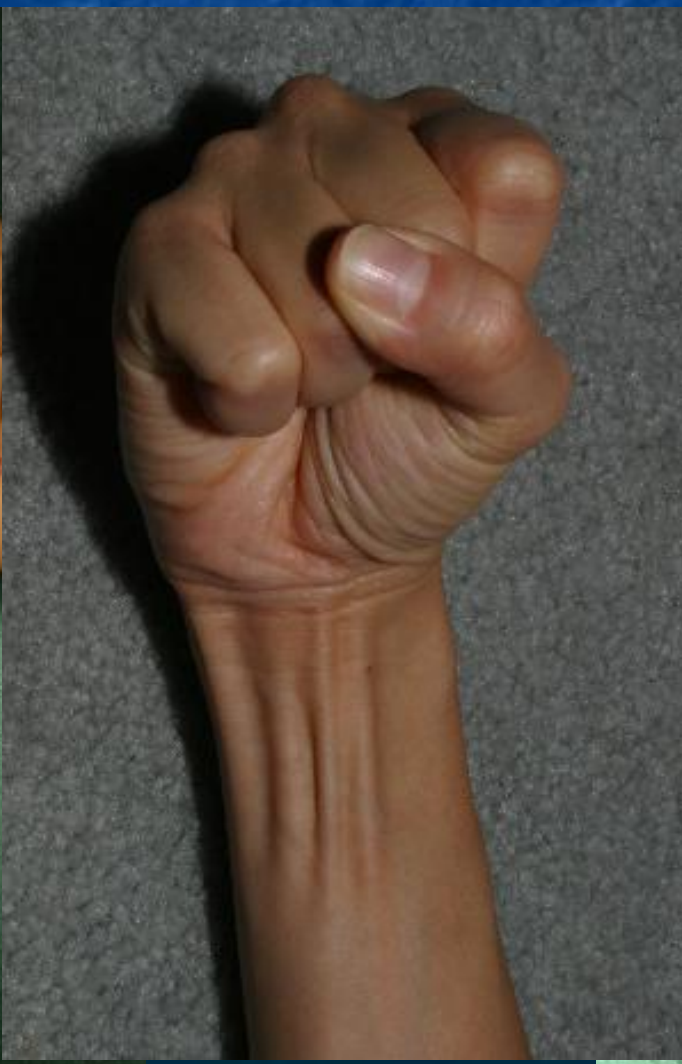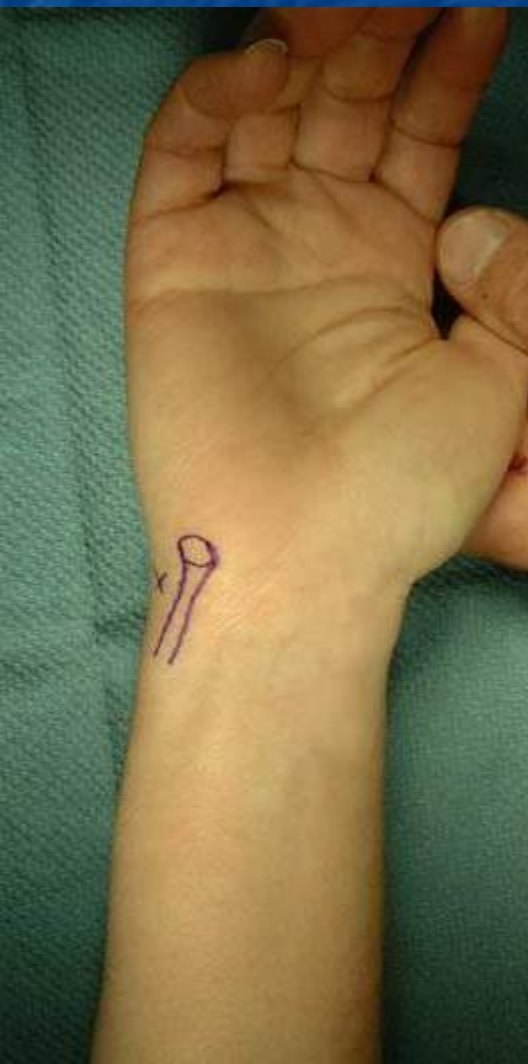Bloqueo del nervio radial



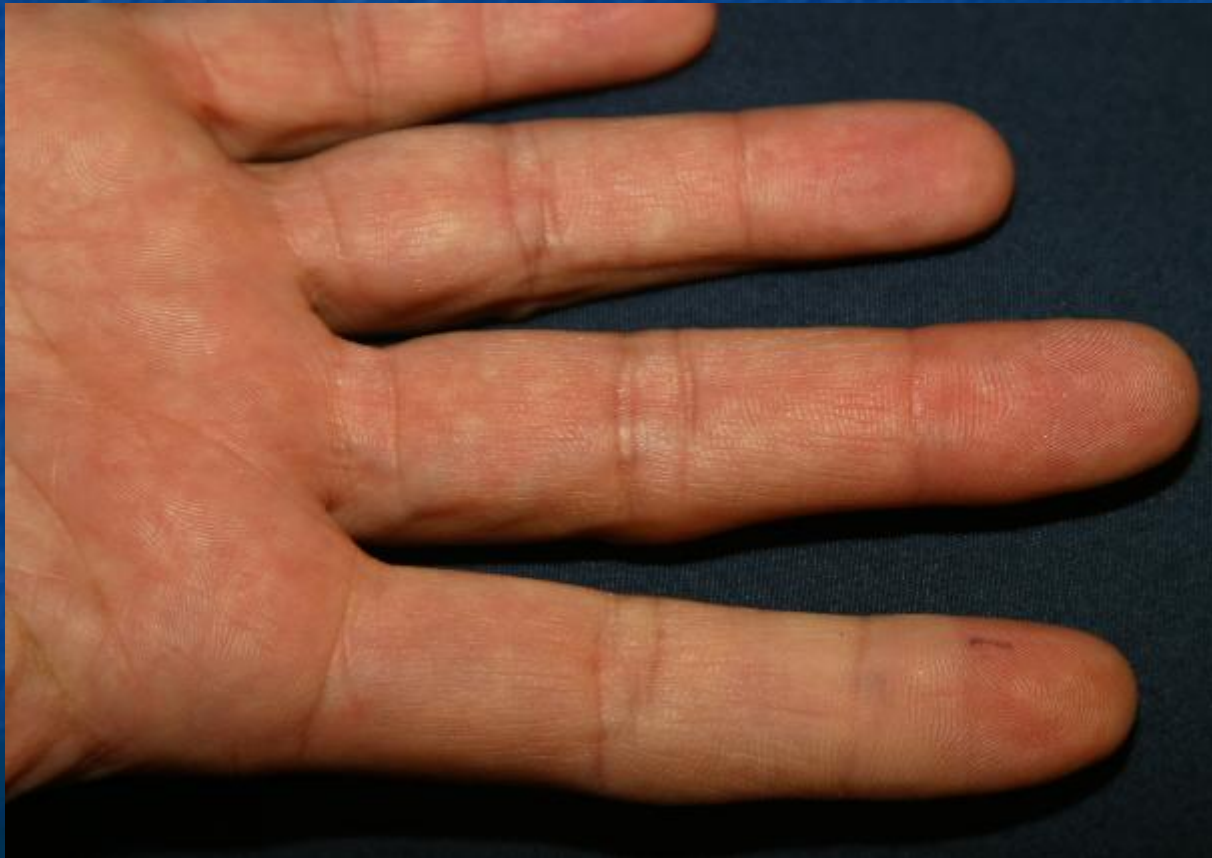Bloqueo del Nervio Mediano



Bloqueo del Nervio Cubito



Dedo del índice inyectado con adrenelina





Bloqueos de los Nervios de la Mano



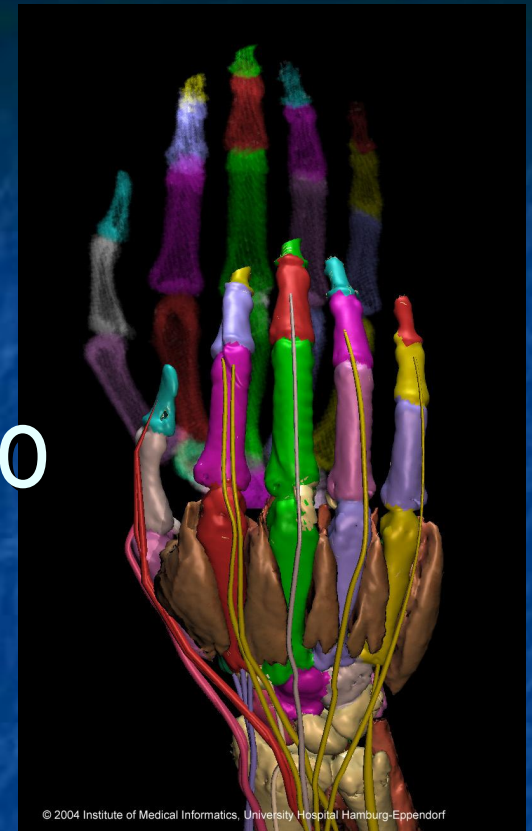
Kevin Reilly, MD

Dept of Emergency Medicine
University of Arizona
Tucson, AZ, USA

Traductor

Kenneth V. Iserson, M.D., MBA

Dept of Emergency Medicine
University of Arizona
Tucson, AZ, USA



© 2004 Institute of Medical Informatics, University Hospital Hamburg-Eppendorf