

Accesos intravenosos

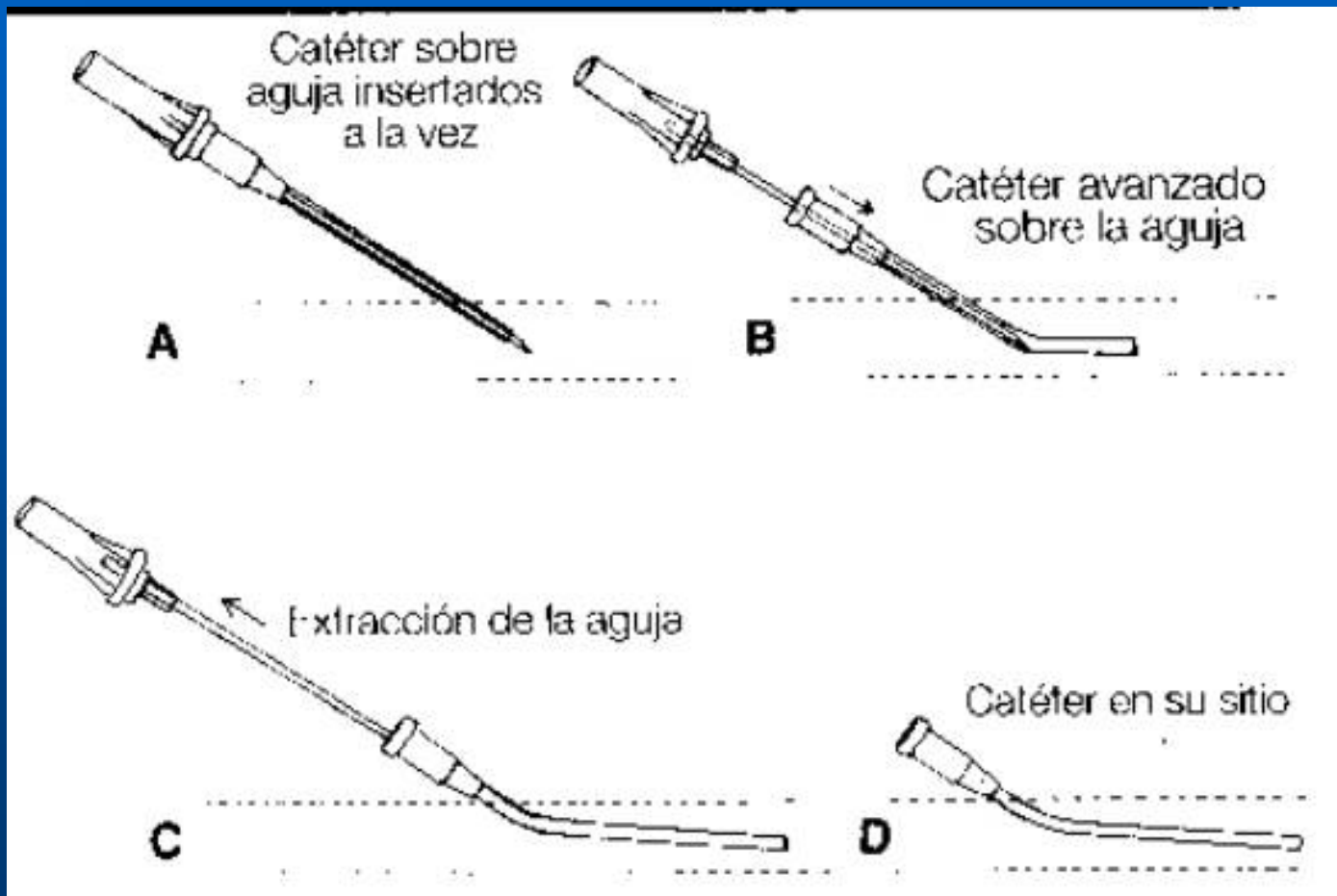


Alberto José Machado, M.D.

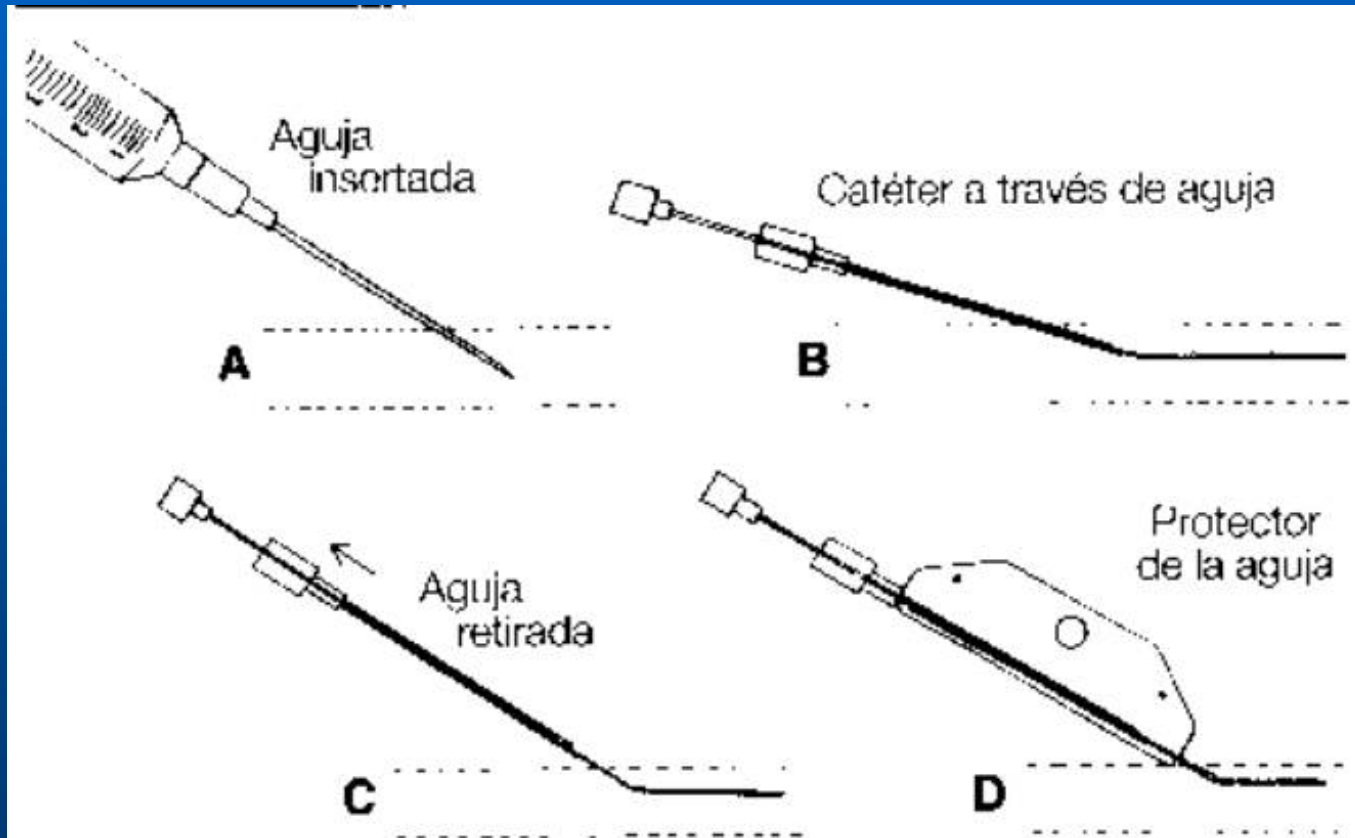
Hospital Alemán

Buenos Aires, Argentina

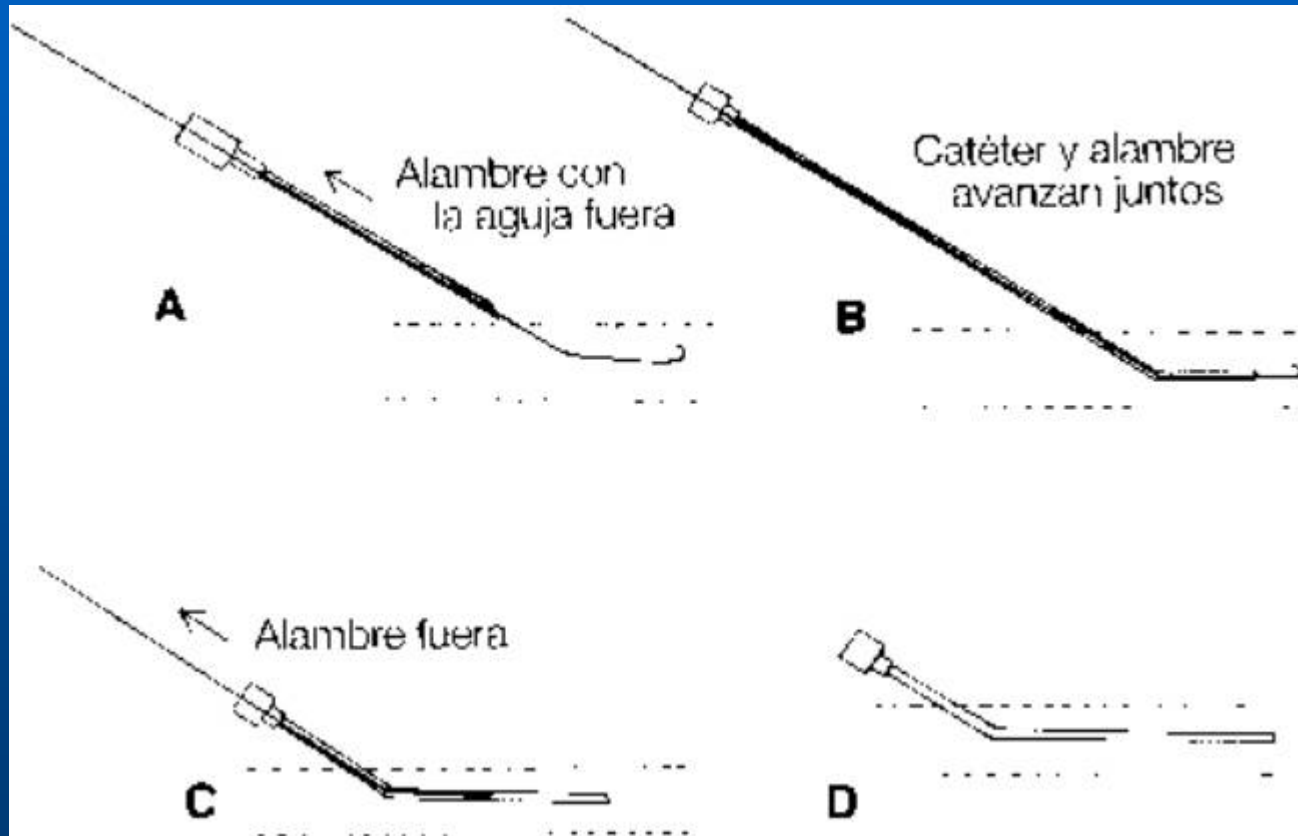
Vía IV: catéter sobre aguja



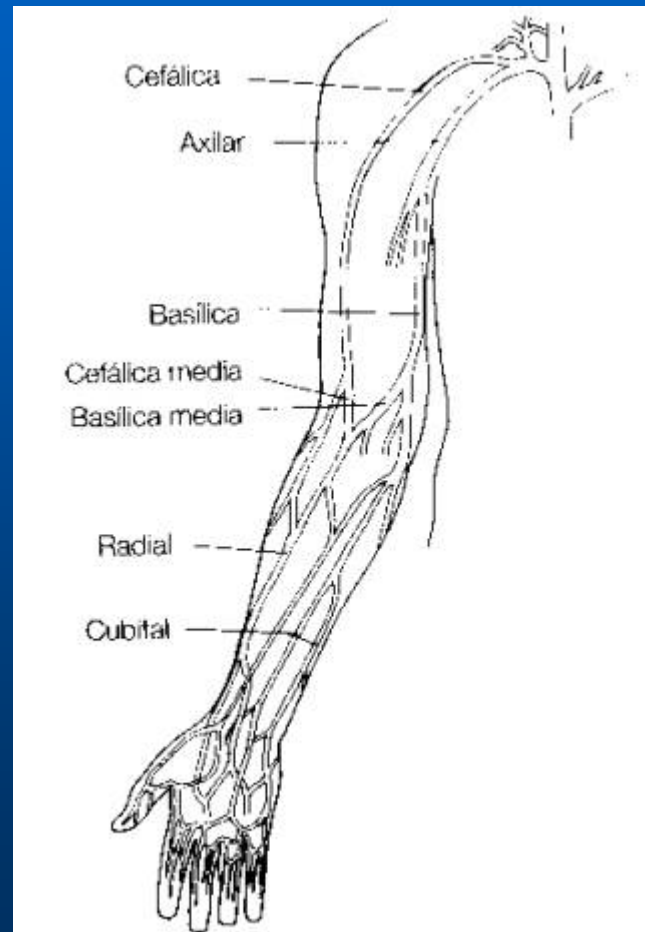
Vía IV: catéter a través de aguja



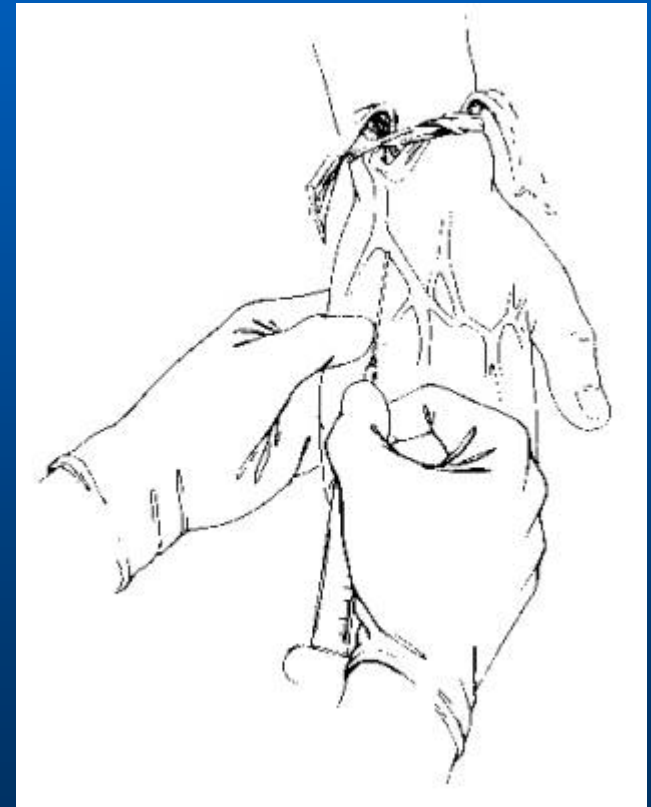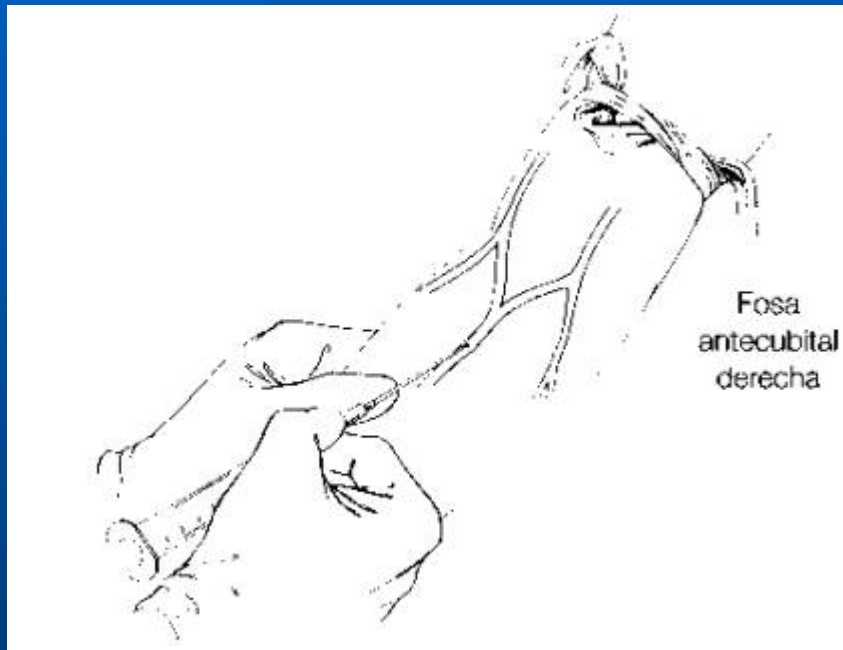
Vía IV: Técnica de Seldinger




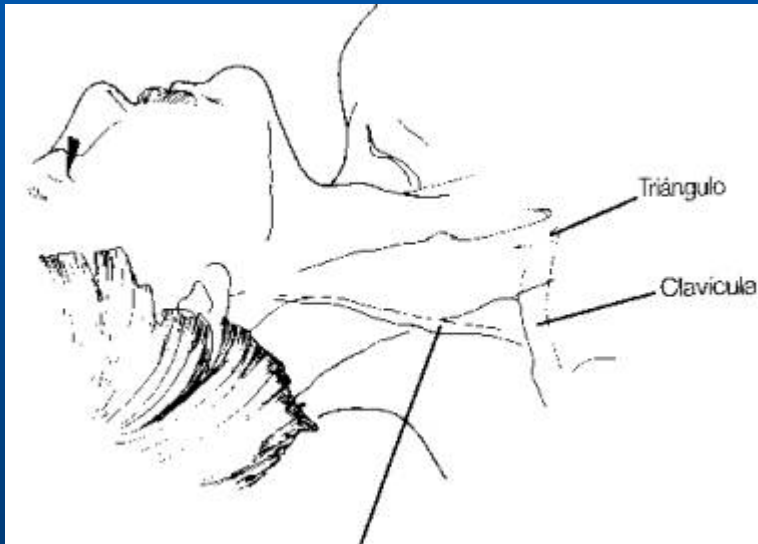
Vía IV: venas periféricas



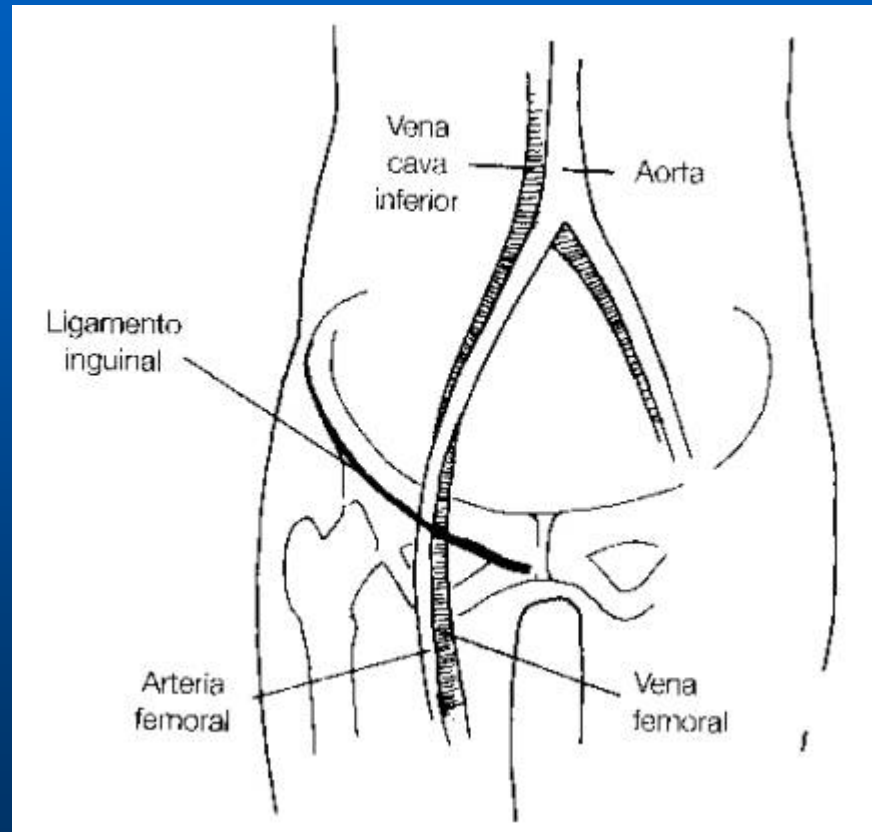
Vía IV: venas periféricas



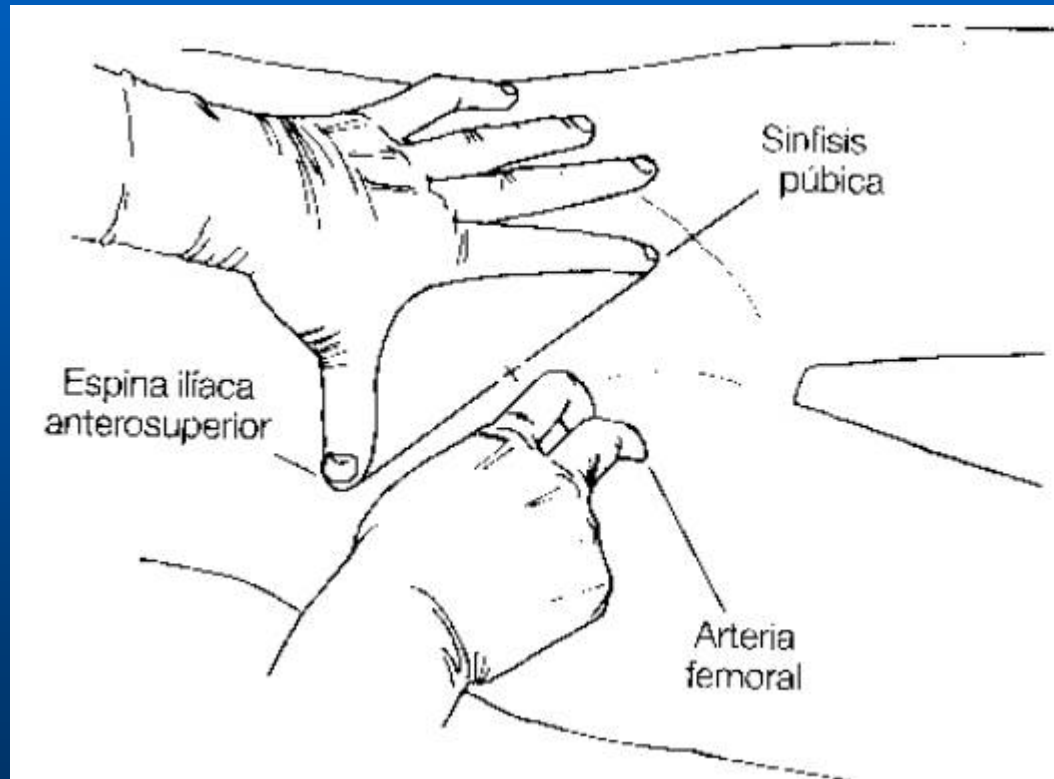
Vía IV: venas periféricas



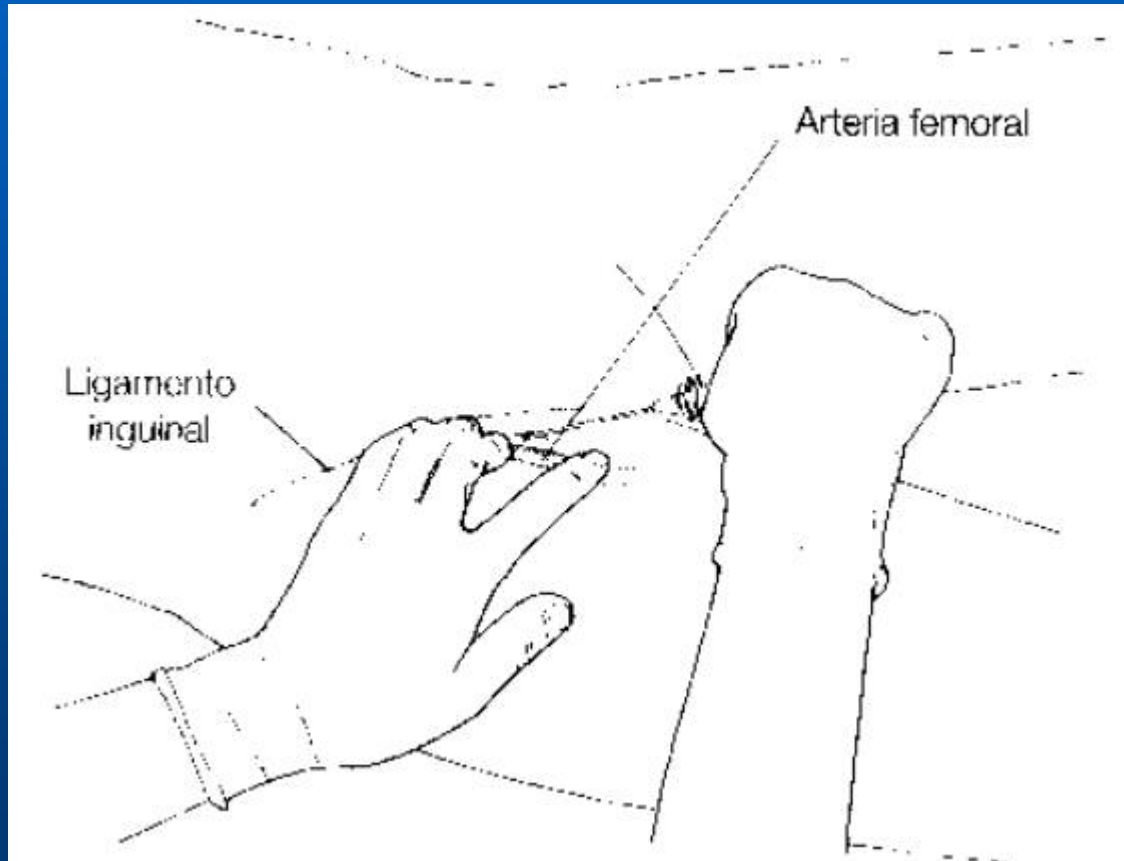
Vía IV: venas periféricas



Vía IV: venas periféricas



Vía IV: venas periféricas



Vía intraósea

